

Case Study

# Chromoblastomycosis successfully treated with the combination of itraconazole and 5-flucytosine



Reginaldo Gon De Lima-Neto<sup>1</sup>, Mohammad Reza Mohammadi<sup>2,\*</sup>



## Article info

Received: 29 Sep 2022

Revised: 13 Nov 2022

Accepted: 15 Jan 2022

Use your device to scan and read the article online



## Keywords:

Occupational Disease, Fungal Infection, Thermoherapy, Chemotherapy, *Fonsecaea Pedrosoi*

## ABSTRACT

Chromoblastomycosis (CBM) is a fungal disease, distributed in tropical and subtropical regions, affecting mainly rural workers. It is characterized by chronic skin lesions that may vary from nodular, tumorous, verrucous or plaque type. Associated constitutional symptoms are rarely found. The histological presentation may yield a pathognomonic feature, the Medlar (sclerotic) bodies, in which a typical brown to black pigment is depicted, explaining “copper pennies” as its alias. In this article, the case of a 56-year-old woman in the countryside of Brazil is reported; whose main complaint was a chronic leg ulcer for the past 8 years. On the left leg, a large, partially ulcerated plaque lesion was found. Microbiological cultures were positive for the pathogen. Histological analysis demonstrated pseudoepitheliomatous hyperplasia, lymphohistiocytic infiltrate and sclerotic bodies (“copper pennies”). CBM’s epidemiological panorama, once established uniquely by geographical distribution, is transitioning to a global health issue, influenced by immunosuppressive conditions, global warming and migration. This scenario demands CBM to be widely considered as a differential diagnosis and may represent a clinical challenge in regions whose professionals have little expertise in infectious tropical diseases.

## 1. Introduction

Chromoblastomycosis (CBM) is a chronic fungal infection of the skin and subcutaneous tissues that often results from direct inoculation, such as from a wood splinter [1]. It emerges as one of the most prevalent transcutaneous traumatic implantation mycoses in individuals living in tropical and subtropical zones around the world [2].

Pedroso and Gomes were the first to observe the disease in 1910 [3], in Sao Paulo, Brazil, reporting it only in 1920 [4, 5]. The first description of CBM is attributed to Max Rudolph, a German physician who published the first cases from the city of Estrela do Sul (Minas Gerais – Brazil), in 1914 [6].

Epidemiological data is derived from

published case reports and surveys. Incidence rates range from 1: 6,800 (14/100,000) in Madagascar to 1: 8,625,000 (0.012/100,000) in the USA [7].

In Brazil, the estimated incidence rate is 3/100,000. Most of the cases in literature occur in Latin America, the Caribbean, Asia, Africa and Australia. Madagascar, Brazil, Mexico, Dominican Republic, Venezuela, India and Southern China contribute to the majority of cases [1, 8, 9].

Several dematiaceous fungi cause chromoblastomycosis, including *Fonsecaea compacta*, *Rhinochrysiella aquaspersa*, *Phialophora verrucosa*, *Fonsecaea pedrosoi* (humid areas) and *Cladophialophora carrionii* (semiarid regions) [10, 11].

<sup>1</sup>Department of Tropical Medicine, Center of Medical Sciences, Federal University of Pernambuco (UFPE), Recife-PE 50740-600, Brazil

<sup>2</sup>Department of Bacteriology, Faculty of Medical Sciences, Tarbiat Modares University, Tehran, Iran

\*Corresponding Author: Mohammad Reza Mohammadi ([mreza\\_mohammadi@modares.ac.ir](mailto:mreza_mohammadi@modares.ac.ir))

Cellular division occurs by internal septation rather than budding. It is believed these agents are soil and/or plant saprobes with typical mycelia in environmental samples, changing morphology to the muriform (sclerotic) form when they are in contact with human tissues [12-15].

The histological presentation may yield a pathognomonic feature in up to 93% of cases: the Medlar (sclerotic) bodies [16]. Also known as muriform cells, these 9-10 microns thick-walled oval structures may be found in the stratum corneum (or other layers of the epidermis) and in granulomas / giant cells. A typical brown to black pigment is depicted, sparing the need for additional stain for identification and explaining “copper pennies” as its alias. The biology of muriform cells is poorly understood, likely representing the adaptive form of these dematiaceous fungi when surviving for prolonged periods in hostile environments [17, 18].

Lymphoplasmacytic infiltration and pseudoepitheliomatous hyperplasia of the *stratum corneum* are the main histological features related to CBM infection. Their presence is estimated at 50% and up to 3%, respectively [10, 19].

Chronic involvements of cutaneous and subcutaneous tissues, associated with a granulomatous, purulent or fibrotic tissue formation, are due to a non-protective humoral immune response [10, 19].

CBM, like most neglected tropical diseases, imposes a clinical challenge. The recalcitrant nature of the chronic and severe late-stage disease and the lack of clinical trials pave the grounds for a mostly treat-and-test therapeutic basis [20].

Options are separated into three categories: physical treatment (surgical excision, thermotherapy, cryosurgery and local heat); chemotherapy (calciferol, fluorocytosine, thiabendazole, amphotericin B, ketoconazole, fluconazole, itraconazole, posaconazole and terbinafine); and combination therapy. Failure may be associated with the host’s underlying

conditions such as undernourishment leading to inadequate immune response; the multitude of etiologic agents; and inadequate chemotherapy [2, 6].

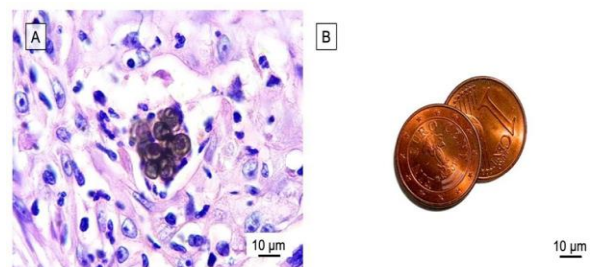
## 2. Case report

On high power, pathognomonic sclerotic bodies (“copper pennies”, Figure 1) were depicted, leading to the diagnosis of Chromoblastomycosis. Cultures on Sabouraud dextrose agar incubated at room temperature were positive for *F. pedrosoi*. Chemotherapy treatment based on itraconazole (ITZ) and flucytosine (5-FC) was introduced.

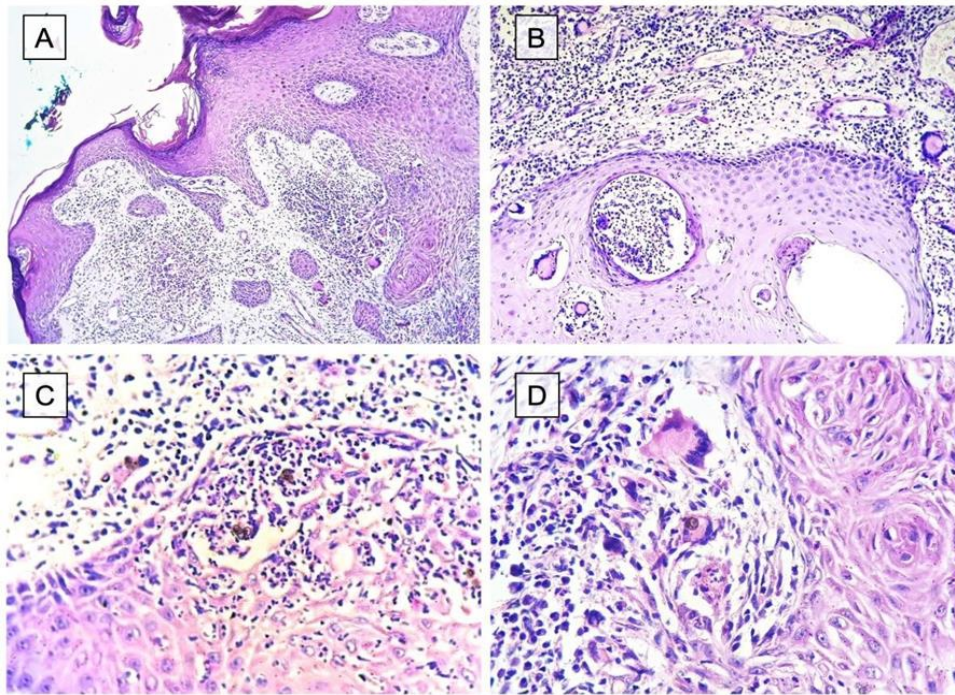
No particular diet was prescribed. The patient remained without evidence of disease progression until the conclusion of this article.

A 56-year-old woman, an agricultural worker, on April 2022 was admitted to the dermatology clinic in the countryside of northern Brazil (Maranhão state region) with a chronic leg ulcer for 8 years. No other symptoms were reported (Figure 2).

At physical examination, a large, partially ulcerated plaque lesion was found on the anterior side of the left leg. Microbiological cultures and a biopsy were performed on its borders. Histological analysis demonstrated intense pseudoepitheliomatous hyperplasia with dense lymphohistiocytic infiltrate (Figure 2).



**Fig. 1.** (A) Sclerotic bodies with their characteristic 9-12 micrometer dimensions, ovoid and pigmented, amidst a dense inflammatory infiltrate (B) Resemblance to “copper pennies” is evident, even considering contemporary Euro pennies (author photograph) (H&E, x630).



**Fig. 2.** (A) Panoramic view of skin biopsy depicting pseudoepitheliomatous hyperplasia with the marked proliferation of stratum corneum, disposed of in an infiltrative-like fashion in the dermal compartment (B) Dense inflammatory infiltrate and epidermal micro-abscess areas with notable multinucleated giant cells (C) Dark structures in the micro-abscess area (D) Multinucleated giant cell with intracytoplasmic minute dark-tinged structures (H&E, x40, x100, x400, x400).

### 3. Discussion

CBM is considered an occupational disease. The lesions are mainly observed on the extremities of outdoor rural workers, with most patients in the age group between 40 to 50 years old, similar to our reported case. According to Santos, who investigated the global burden of CBM by published literature between 1914 and 2020 with a total of 7,740 patients, the median age was 52.5 years, and the main site involved were the lower limbs (56.7%). In addition, the authors found a total of 3,817 fungal isolates were cultured, 3,089 (80.9%) *Fonsecaea* spp. These results fully agree with our case report [21]. The main associated risk factors are lack of protective shoes, gloves or garments; poor nutrition and hygienic habits [10]. Skin lesions are the most common clinical presentation. The primary lesion (at the site of inoculation) is a pink papule, and it further progresses to a verrucous plaque. Skin forms may vary from nodular, tumorous, verrucous and plaque type [2], sometimes imposing a diagnostic challenge. Herein, clinical, histopathological, and mycological findings were compatible with the diagnosis of CBM.

A greater challenge than diagnosis is the treatment. Treatment options are suggested based on clinical experience by reports of non-comparative studies and case series instead of well-conducted clinical trials. In our patient, combined therapy with ITZ and 5-FC was used with good clinical response, although the most common antifungal association is ITZ and terbinafine. reported an interesting case of severe chromoblastomycosis mistreated over 20 years, which was successfully treated with ITZ and 5-FC association [22, 23]. Flucytosine is a pyrimidine derivative and antimetabolite agent, with its main activity in inhibiting the synthesis of nucleic acids in fungal cells. It is classified as a systemic antifungal and approved by FDA for the treatment of invasive candidiasis and cryptococcal meningitis.

Due to the unavailability of 5-FC, there are no comparative analyzes or clinical trials in Brazil [24]. Usually, there are no associated constitutional symptoms. Cases of squamous cell carcinoma (SCC) arising from a chronic inflammatory microenvironment (Marjolin ulcer phenomenon) with CBM as the underlying etiologic agent have been widely

reported [25, 26]. A Brazilian series of 100 cases with a 14-year follow-up period found an incidence of SCC around 2% [18]. CMB and SCC are differential diagnoses that should be mutually excluded, especially in broad and chronic limb lesions [25].

In terms of histological evaluation, care should be taken to exclude concomitant fungal infection (Paracoccidioidomycosis) and fungal mimickers such as Phaeoerythromycosis with “copper penny” spore-like organisms, commonly seen as dermal-based pseudocyst, an abscess or ulcerated necrotic granulomas [27, 28]. Anecdotal reports have also described melanoma as a mimicker [17].

In 2018, as it might be starting a third wave of non-desired immunosuppressive related diseases (IRD) due to global warming, CBM should be considered a differential diagnosis in a multitude of clinical scenarios. In the 1980s, when HIV infection emerged [29], the first wave of IRD was reported, varying from opportunistic co-infections to increased cancer risk [30].

Organ transplantation fostered the second wave of IRD due to immunosuppressive therapy [31]. Global warming, in a similar fashion, tends to swift the epidemiological profile of many infectious diseases. The expected thermal increase up to 5.8°C by the end of this century might cause tropical/subtropical conditions to appear in temperate climates. The West Nile Virus, for example, previously restricted to the southern and southwestern regions of the United States, has been already notified in eastern states [32]. Similarly, the risk of Lyme disease has significantly increased in northern states from 1993 to 2007 [33].

In a global health scenario, other factors to be considered are the heterogeneous populations and their transit. Migration and asylum-seeking can lead to unexpected diagnoses, determining the need to adapt the approach to public health issues in some countries [34-36]. Consequently, an increased awareness of tropical/subtropical infectious disease features, as provided by this report, is mandatory for accurate diagnosis and treatment.

#### 4. Conclusion

Ulcerative skin lesions, a common scenario in developing countries, may present a wide range of differential diagnoses, from fungal infections to squamous cell carcinoma. In this report, we have illustrated a classical histopathological case in which the pathologist must find muriform bodies to define the diagnosis of Chromoblastomycosis. In clinical terms, the suspicion should be followed by a biopsy of the lesion; in pathological terms, findings such as granulomatous response, the presence of giant cells, pseudoepitheliomatous hyperplasia and diffuse lymphohistiocytic infiltrate should warrant the search for epidermal or dermal sclerotic (Medlar) bodies. Their identification should spare the need for additional stains.

Treatment imposes a clinical challenge due to a myriad of facts: the chronicity, the difficulty in identifying of correct pathogen and the accompanying social panorama. However, we suggest that the combination therapy of ITZ and 5-FC should be an option to be considered in CBM unresponsive cases treated by either monotherapy or association with ITZ and terbinafine. Once restricted to specific climates, Chromoblastomycosis might face an epidemiological swift in a globalized scenario; therefore, the knowledge of its clinical and pathological features is of utmost importance for pathologists.

#### Conflict of interest

The authors declare that there is no conflict of interest to publish this manuscript.

#### Author contributions

All authors read and approved the final manuscript.

#### Consent for publications

All authors have read and approved the final manuscript for publication

#### Data Availability Statement

All data generated or analyzed in this study are available from the corresponding author upon reasonable request.

### Ethics approval and consent to participate

This study was approved by the ethics committee of the Nucleo de Medicina Tropical, UFPA, with the ethical code in research: 19257719.5.

### Funding

This research did not receive any specific grant from funding agencies in the public, commercial, or not-for-profit sectors.

### References

- Queiroz-Telles F (2015) Chromoblastomycosis: a neglected tropical disease. *Revista do Instituto de Medicina Tropical de São Paulo* 57: 46-50. doi: <https://doi.org/10.1590/S0036-46652015000700009>
- Queiroz-Telles F, Esterre P, Perez-Blanco M, Vitale RG, Salgado CG, Bonifaz A (2009) Chromoblastomycosis: an overview of clinical manifestations, diagnosis and treatment. *Medical mycology* 47 (1): 3-15. doi: <https://doi.org/10.1080/13693780802538001>
- Criado PR, Valente NYS, Brandt HRC, Belda Junior W, Halpern I (2010) Pedroso and Gomes' verrucous Dermatitis (Chromoblastomycosis): 90 years on and still among us. *Anais Brasileiros de Dermatologia* 85: 104-105. doi: <https://doi.org/10.1590/S0365-05962010000100018>
- Defendi L, Morgantetti G, De Medeiros G, Balancin M (2023) Chromoblastomycosis: a tropical-subtropical fungal disease with pathognomonic features not to be neglected in a global health scenario. *Clin Res Commun* 6 (1): 1-4. doi: <https://doi.org/10.53388/CRC2023001>
- Pedroso A, Gomes J (1920) Sobre quatro casos de dermatite verrucosa produzida por *Phialophora verrucosa*. *An Paul Med Cir* 11: 53-56. doi:
- Rudolph M (1914) Über die brasilianische "Figueira"(Vorläufige Mitteilung). *Arch Schiffs Tropen-Hyg* 18: 498-499. doi:
- Marques GF, Masuda PY, Sousa JMP, Barreto JA, Wachholz PA (2015) Clinical and demographic profile of chromoblastomycosis in a referral service in the midwest of São Paulo state (Brazil). *Anais brasileiros de dermatologia* 90: 140-142. doi: <https://doi.org/10.1590/abd1806-4841.20153252>
- Lu S, Lu C, Zhang J, Hu Y, Li X, Xi L (2013) Chromoblastomycosis in Mainland China: a systematic review on clinical characteristics. *Mycopathologia* 175: 489-495. doi: <https://doi.org/10.1007/s11046-012-9586-z>
- Chanda K (2021) An overview on the therapeutics of neglected infectious diseases—Leishmaniasis and Chagas diseases. *Frontiers in Chemistry* 9: 622286. doi: <https://doi.org/10.3389/fchem.2021.622286>
- Avelar-Pires C, Simoes-Quaresma JA, Moraes-de Macedo GM, Brasil-Xavier M, Cardoso-de Brito A (2013) Revisiting the clinical and histopathological aspects of patients with chromoblastomycosis from the Brazilian Amazon region. *Archives of medical research* 44 (4): 302-306. doi: <https://doi.org/10.1016/j.arcmed.2013.04.008>
- Gomes RR, Vicente VA, Azevedo CMd, Salgado CG, da Silva MB, Queiroz-Telles F, Marques SG, Santos DW, de Andrade TS, Takagi EH (2016) Molecular epidemiology of agents of human chromoblastomycosis in Brazil with the description of two novel species. *PLoS neglected tropical diseases* 10 (11): e0005102. doi: <https://doi.org/10.1371/journal.pntd.0005102>
- Jiang N, Voglmayr H, Piao CG, Li Y (2021) Two new species of Diaporthe (Diaporthaceae, Diaporthales) associated with tree cankers in the Netherlands. *MycKeys* 85: 31-56. doi: <https://doi.org/10.3897/mycokeys.85.73107>
- Kokina A, Tanilas K, Ozolina Z, Pleiko K, Shvirksts K, Vamza I, Liepins J (2021) Purine Auxotrophic Starvation Evokes Phenotype Similar to Stationary Phase Cells in Budding Yeast. *Journal of fungi (Basel, Switzerland)* 8 (1). doi: <https://doi.org/10.3390/jof8010029>
- Schroeder K, Heinrich K, Neuwirth I, Jonas K (2021) The Chaperonin GroESL Facilitates *Caulobacter crescentus* Cell Division by Supporting the Functions of the Z-Ring Regulators FtsA and FzIA. *mBio* 12

- (3). doi: <https://doi.org/10.1128/mBio.03564-20>
15. Xie XX, Nuerla A, Balati M, Zhong NF, Li NX (2022) Typical Pesticide Residues and Their Risk Assessment in Farmland Environment of Different Plant Types in Shaya County, Xinjiang. *Huan jing ke xue= Huanjing kexue* 43 (8): 4154-4165. doi: <https://doi.org/10.13227/j.hjcx.202110020>
  16. Correia RTM, Valente N, Criado PR, Martins JEdC (2010) Chromoblastomycosis: study of 27 cases and review of medical literature. *Anais brasileiros de dermatologia* 85: 448-454. doi: <https://doi.org/10.1590/S0365-05962010000400005>
  17. Bui AQ, Espana EM, Margo CE (2012) Chromoblastomycosis of the conjunctiva mimicking melanoma of the ciliary body. *Archives of Ophthalmology* 130 (12): 1615-1617. doi: <https://doi.org/10.1001/archophthalmol.2012.1573>
  18. Roy AD, Das D, Deka M (2013) Chromoblastomycosis–A clinical mimic of squamous carcinoma. *The Australasian Medical Journal* 6 (9): 458. doi: <https://doi.org/10.4066%2FAMJ.2013.1806>
  19. Queiroz-Telles F, de CL Santos DW (2013) Challenges in the therapy of chromoblastomycosis. *Mycopathologia* 175: 477-488. doi: <https://doi.org/10.1007/s11046-013-9648-x>
  20. Falci R, Queiroz-Telles F, Fahal A, Falci D, Caceres D, Chiller T, Pasqualotto A (2017) Fungal infections 4 neglected endemic mycoses. *Lancet Infect Dis* 17: e367-e377. doi: [https://doi.org/10.1016/S1473-3099\(17\)30306-7](https://doi.org/10.1016/S1473-3099(17)30306-7)
  21. Santos DWC, de Azevedo CdMPeS, Vicente VA, Queiroz-Telles F, Rodrigues AM, de Hoog GS, Denning DW, Colombo AL (2021) The global burden of chromoblastomycosis. *PLoS Neglected Tropical Diseases* 15 (8): e0009611. doi: <https://doi.org/10.1371/journal.pntd.0009611>
  22. Coelho RA, Alves GM, Figueiredo-Carvalho MHG, Almeida-Silva F, de Souza GR, Lourenço MCdS, Brito-Santos F, Amaral ACF, Almeida-Paes R (2022) New possibilities for chromoblastomycosis and phaeohyphomycosis treatment: identification of two compounds from the MMV Pathogen Box® that present synergism with itraconazole. *Memórias do Instituto Oswaldo Cruz* 117: 1-9. doi: <https://doi.org/10.1590/0074-02760220089>
  23. Antonello VS, Silva MCA, Cambuzzi E, Kliemann DA, Santos BR, Queiroz-Telles F (2010) Treatment of severe chromoblastomycosis with itraconazole and 5-flucytosine association. *Revista do Instituto de Medicina Tropical de São Paulo* 52: 329-331. doi: <https://doi.org/10.1590/S0036-46652010000600008>
  24. Padda IS, Parmar M (2022) Flucytosine. In: *StatPearls* [Internet]. StatPearls Publishing; Copyright © 2022, StatPearls Publishing LLC, p Bookshelf ID: NBK557607
  25. Bazaliński D, Przybek-Mita J, Barańska B, Więch P (2017) Marjolin's ulcer in chronic wounds–review of available literature. *Contemporary Oncology/Współczesna Onkologia* 21 (3): 197-202. doi: <https://doi.org/10.5114/wo.2017.70109>
  26. Minotto R, Bernardi CDV, Mallmann LF, Edelweiss MIA, Scroferneker ML (2001) Chromoblastomycosis: a review of 100 cases in the state of Rio Grande do Sul, Brazil. *Journal of the American Academy of Dermatology* 44 (4): 585-592. doi: <https://doi.org/10.1067/mjd.2001.112220>
  27. Skupsky H, Junkins-Hopkins J (2017) Counterfeit pennies: distinguishing chromoblastomycosis from phaeohyphomycotic infections. *The American Journal of Dermatopathology* 39 (6): 485-487. doi: <https://doi.org/10.1097/DAD.0000000000000679>
  28. Krzyściak PM, Pindycka-Piaszczyńska M, Piaszczyński M (2014) Chromoblastomycosis. *Adv Dermatology Allergol* 31: 310-321. doi: <https://doi.org/10.5114/pdia.2014.40949>
  29. Chang CC, Crane M, Zhou J, Mina M, Post JJ, Cameron BA, Lloyd AR, Jaworowski A, French MA, Lewin SR (2013) HIV and co-infections. *Immunological reviews* 254 (1): 114-142. doi: <https://doi.org/10.1111/imr.12063>
  30. Silverberg MJ, Chao C, Leyden WA, Xu L, Tang B, Horberg MA, Klein D, Quesenberry Jr CP, Towner WJ, Abrams DI (2009) HIV infection and the risk of cancers with and without a known infectious cause. *Aids* 23 (17): 2337-2345. doi: <https://doi.org/10.1097/qad.0b013e3283319184>
  31. George MP, Masur H, Norris KA, Palmer SM, Clancy CJ, McDyer JF (2014) Infections in the immunosuppressed host. *Annals of the American Thoracic Society* 11 (Supplement 4): S211-S220. doi: <https://doi.org/10.1513/annalsats.201401-038pl>
  32. Soverow JE, Wellenius GA, Fisman DN, Mittleman MA (2009) Infectious disease in a warming world: how weather influenced West Nile virus in the United States (2001–2005). *Environmental health perspectives* 117 (7):

- 1049-1052. doi: <https://doi.org/10.1289/ehp.0800487>
33. Tuite AR, Greer AL, Fisman DN (2013) Effect of latitude on the rate of change in incidence of Lyme disease in the United States. Canadian Medical Association Open Access Journal 1 (1): E43-E47. doi: <https://doi.org/10.9778/cmajo.20120002>
34. Lopez-Velez R, Huerga H, Turrientes M (2003) Infectious diseases in immigrants from the perspective of a tropical medicine referral unit. The American journal of tropical medicine and hygiene 69 (1): 115-121. doi:
35. Castelli F, Sulis G (2017) Migration and infectious diseases. Clinical Microbiology and Infection 23 (5): 283-289. doi: <https://doi.org/10.1016/j.cmi.2017.03.012>
36. Pareek M, Greenaway C, Noori T, Munoz J, Zenner D (2016) The impact of migration on tuberculosis epidemiology and control in high-income countries: a review. BMC medicine 14: 1-10. doi: <https://doi.org/10.1186/s40985-017-0065-4>



Copyright © 2023 by the author(s). This is an open access article distributed under the terms and conditions of the Creative Commons Attribution (CC BY) license (<https://creativecommons.org/licenses/by/4.0/>)

#### How to Cite This Article:

Lima-Neto RGD, Mohammadi MR (2023) Chromoblastomycosis successfully treated with the combination of itraconazole and 5-flucytosine. Cellular, Molecular and Biomedical Reports 3 (3): 145-151. doi: 10.55705/cmbr.2023.378135.1092

#### Download citation:

[RIS](#); [EndNote](#); [Mendeley](#); [BibTeX](#); [APA](#); [MLA](#); [HARVARD](#); [VANCOUVER](#)